

## Total Cranial Vault Segmentation: Method and Grading Rubric

Phong Vuong, David Drucker, Chris Schwarz, Evan Fletcher, Charles DeCarli, and Owen Carmichael, for the Alzheimer's Disease Neuroimaging Initiative

Contents	
Page 1-2	Summary and Method
Page 3-9	Grade Rubric

### Summary

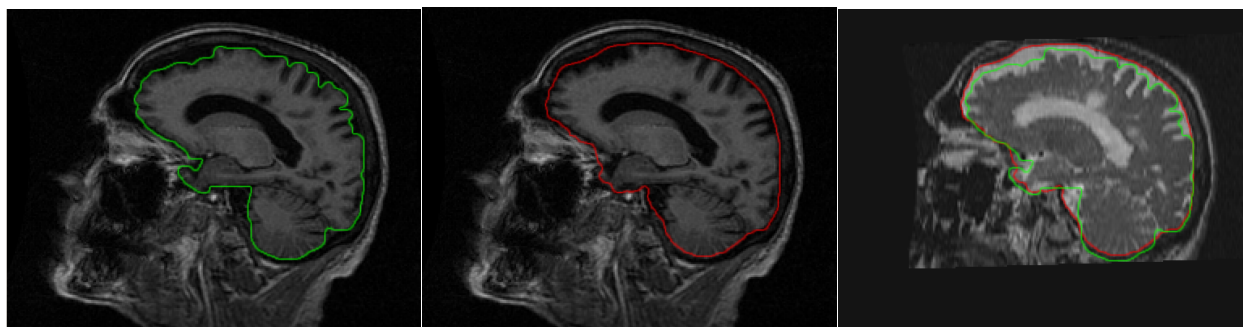
The quality of the total cranial vault segmentation using DSE T2 weighted MRI brain scans have been verified and individually graded. The scale ranges from zero to three with three indicating excellent TCV segmentation and zero indicating unacceptable TCV segmentation. There are a total of 819 subjects in the ADNI 1 study. We have estimated total cranial volumes for 810 subjects. The remaining 9 subjects have poor intra patient scan alignment between the 3DT1 and DSE T2 weighted MRI image which invalidates our TCV segmentation pipeline. There are 300 TCV segmentations with a grade rating of 3, and 510 TCV segmentations with a grade rating of 2. None have a grade rating of 1 or 0.

The total cranial volume of the brain is defined to include all the white matter, gray matter, and cerebrospinal fluid within the cranial vault.

### Method

Estimating the total cranial volume requires co-registration and brain extraction steps as pre-requisites. For each patient in the ADNI 1 database, we performed the TCV segmentation step using T1-weighted and T2-weighted MRI brain scans collected during the baseline evaluation. The T2-weighted MRI brain scans were linearly co-registered to the corresponding T1-weighted scan. The brain surface, including parenchyma and ventricular and sulcal CSF, had been semi-automatically traced on the T1-weighted scan using the Brain Extraction Tool (BET) followed by manual cleanup. Our TCV segmentation program extended this brain surface to the outer boundary of the CSF within the cranial vault, based on T2-weighted imagery.



The TCV segmentation algorithm began by establishing a 3D surface mesh fitted to the brain surface. The points were then ballooned outward towards the edge of the cranial CSF based on the T2-weighted image. This amounted to expanding points outward until they hit a bright-to-dark boundary, with bright representing CSF and dark representing other surrounding tissue.



**Figure 1.** (Left) Sagittal slice of a T1-weighted MRI with the brain surface segmentation outlined in green. (Middle) T1-weighted MRI with the T2-based TIV segmentation outlined in red. Note that in the superior prefrontal cortex, the correct position of the TIV surface is non-obvious based on T1-weighted image intensities. (Right) Co-registered T2-weighted MRI with the brain surface and TIV segmentations from the left and middle images overlaid in green and red.

## Grade Rubric

The total cranial volume brain binary masks have been quality controlled and graded to reflect the accuracy of the TCV segmentation. The grades are scaled from 0 to 3, where a rating of 3 denotes excellent TCV segmentation with little to no error, and a rating of 0 denotes unacceptable TCV segmentation with noticeable errors.

Scale	Description
3	<p>Excellent</p> <ul style="list-style-type: none"> <li>The brain segmentation matches well with the boundary of the brain region</li> <li>The brain segmentation may be off by a few voxels in some areas, however this does not significantly affect the volume estimation.</li> </ul> <div style="display: flex; justify-content: space-around;"> <div style="text-align: center;">  <p>Figure 3.1</p> </div> <div style="text-align: center;">  <p>Figure 3.2</p> </div> </div>

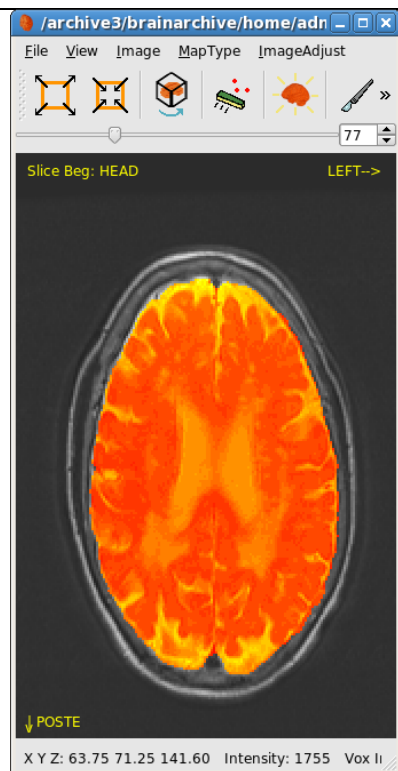


Figure 3.3

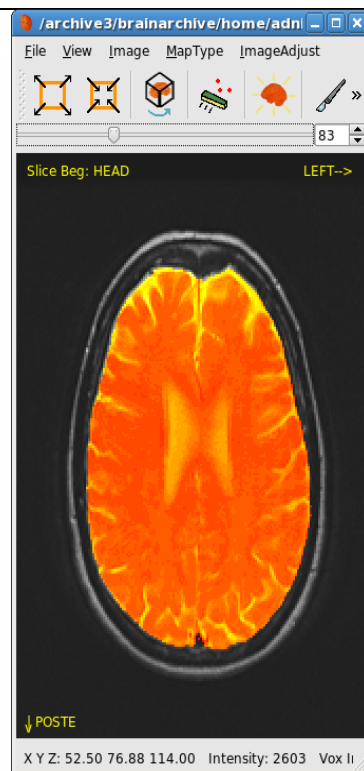


Figure 3.4

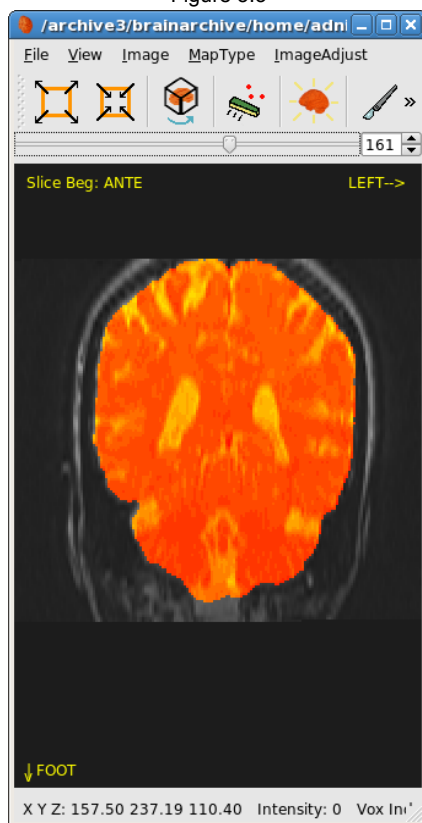


Figure 3.5

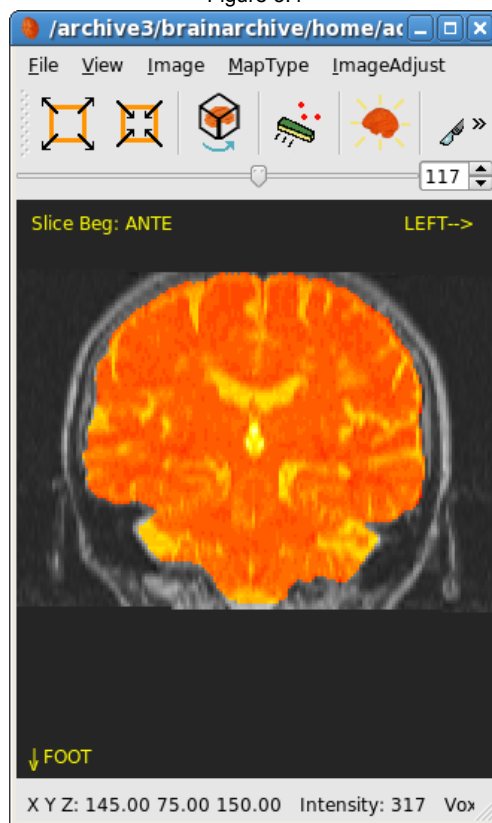


Figure 3.6

2

Good

- The rest of the segmentation should match the boundary of the brain but one region may be over segmented or under segmented.
- The error in this region should not greatly affect the estimation of the total cranial volume.

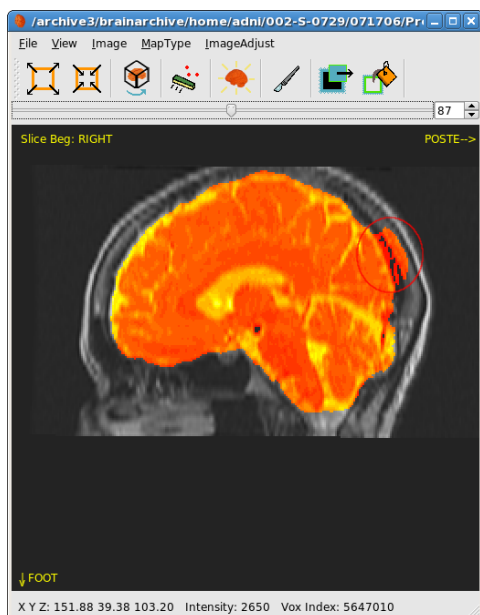

Figure 2.1

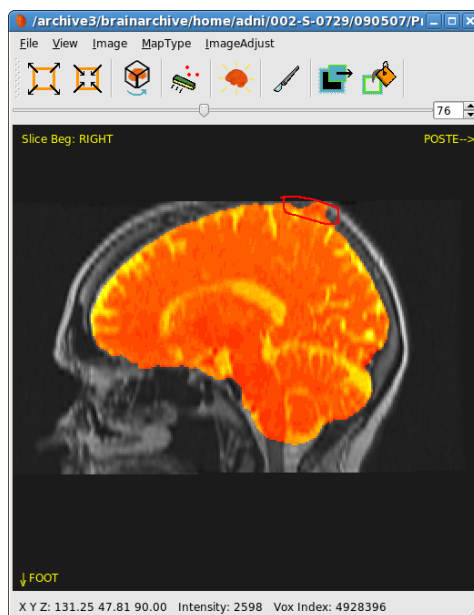


Figure 2.2

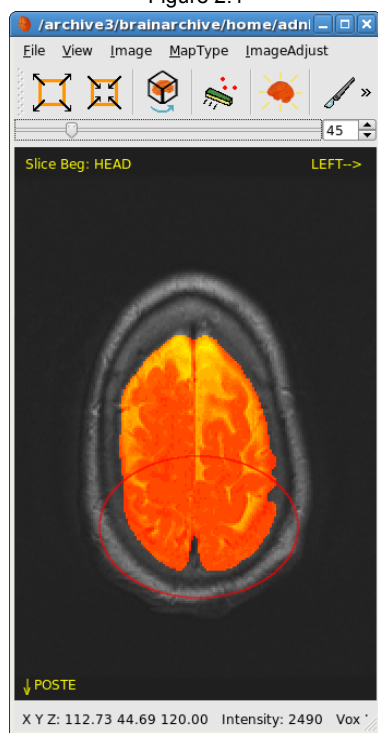


Figure 2.3

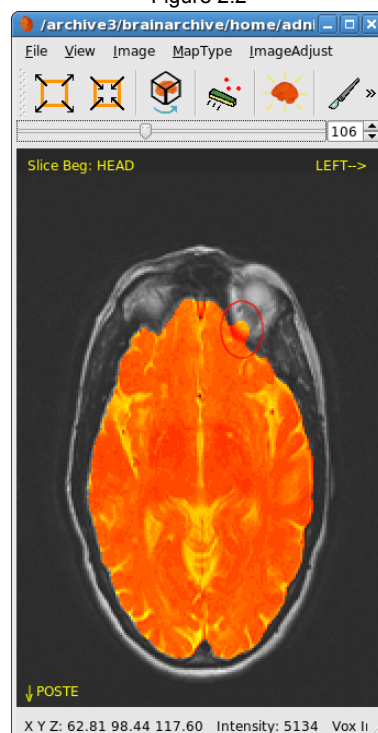


Figure 2.4

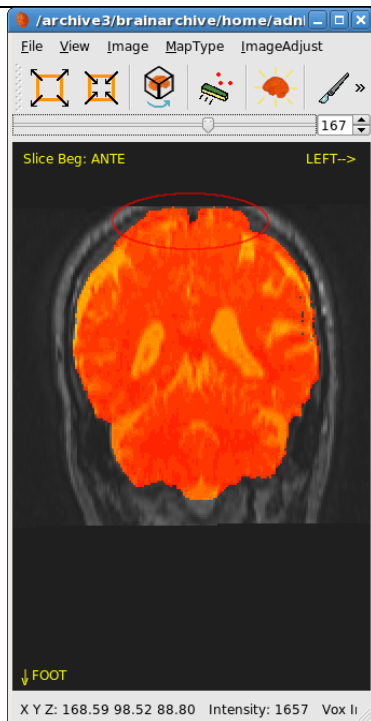


Figure 2.5

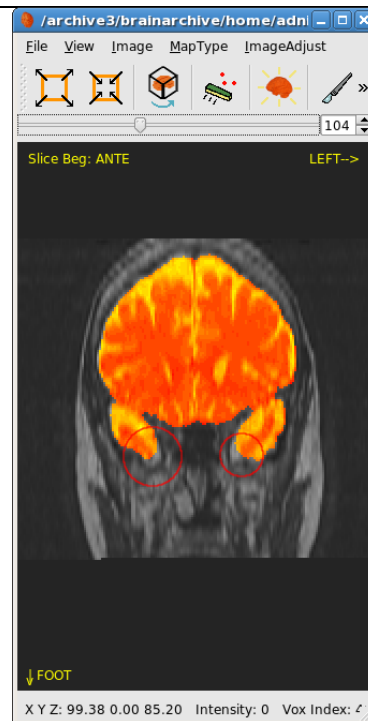


Figure 2.6

1

#### Unsatisfactory

- The rest of the segmentation should match the boundary of the brain region but more than one region may be over segmented or under segmented
- The volume estimated from the TCV segmentation may be affected.
- The segmentation is less ideal and needs to be cleaned up.

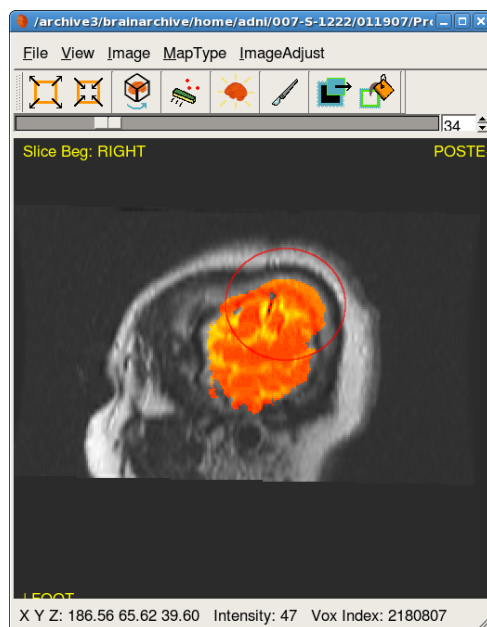

Figure 1.1

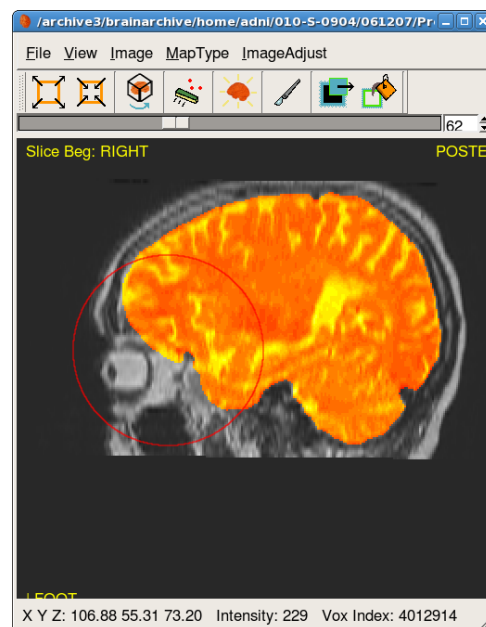

Figure 1.2

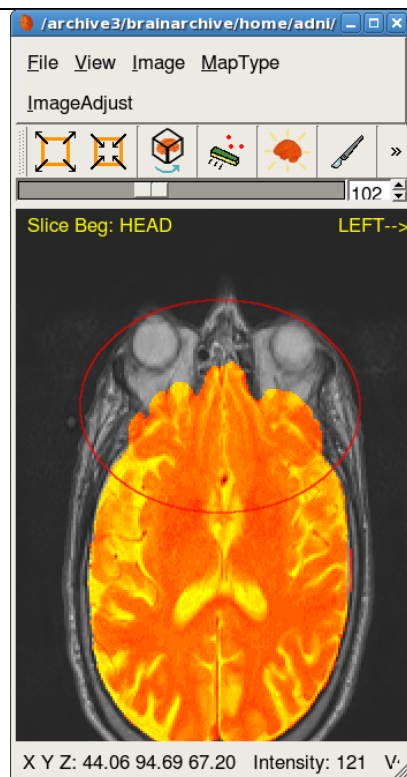

Figure 1.3

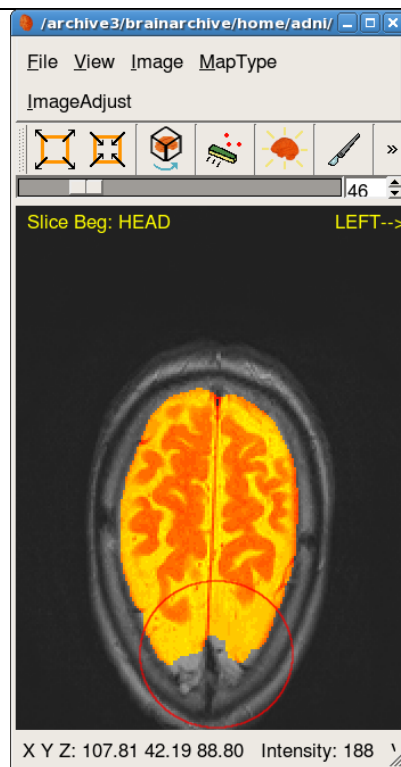


Figure 1.4

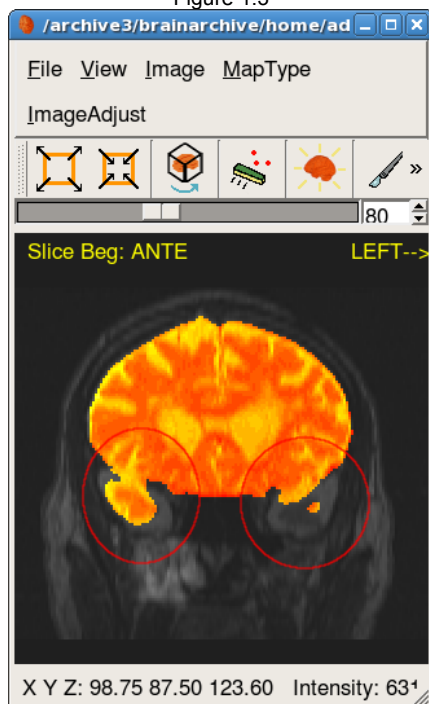


Figure 1.5

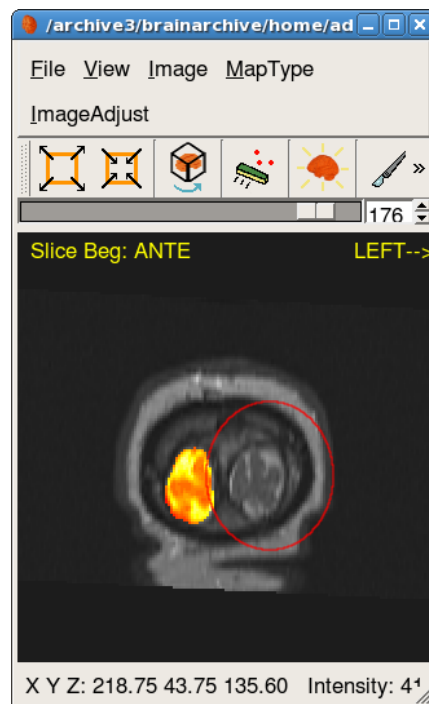


Figure 1.6



0

## Unacceptable

- The brain segmentation does not match the boundary of the brain in several regions
- These regions contain significant error, which may invalidate the brain volume estimation.
- The brain segmentation must be redone.

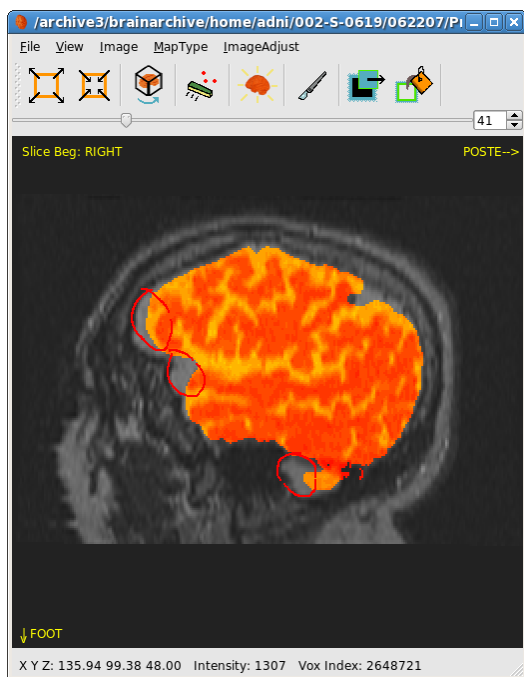


Figure 0.1

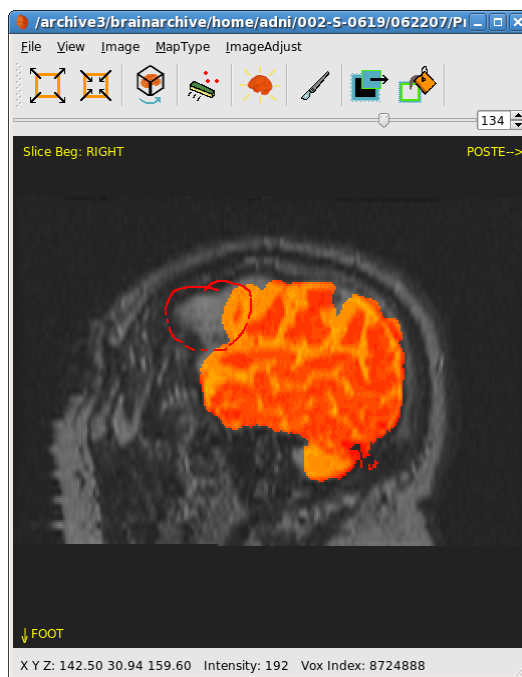


Figure 0.2

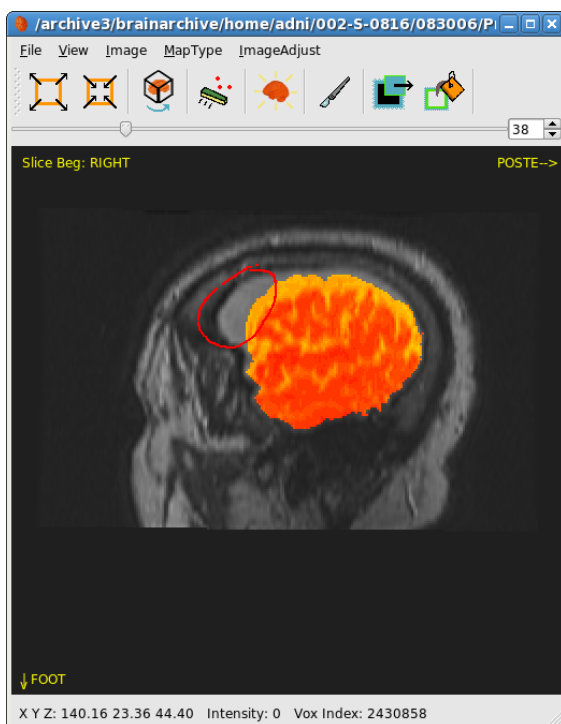

Figure 0.3

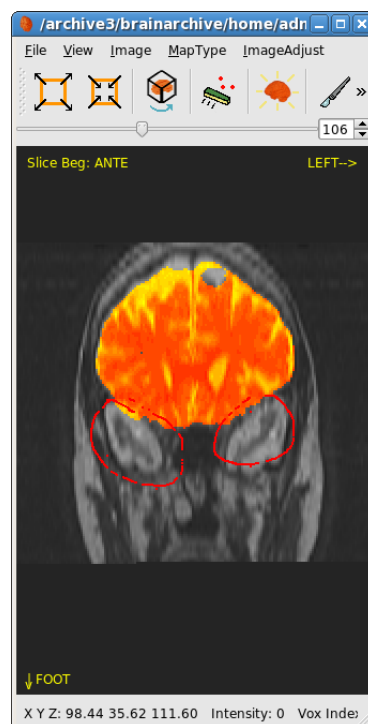
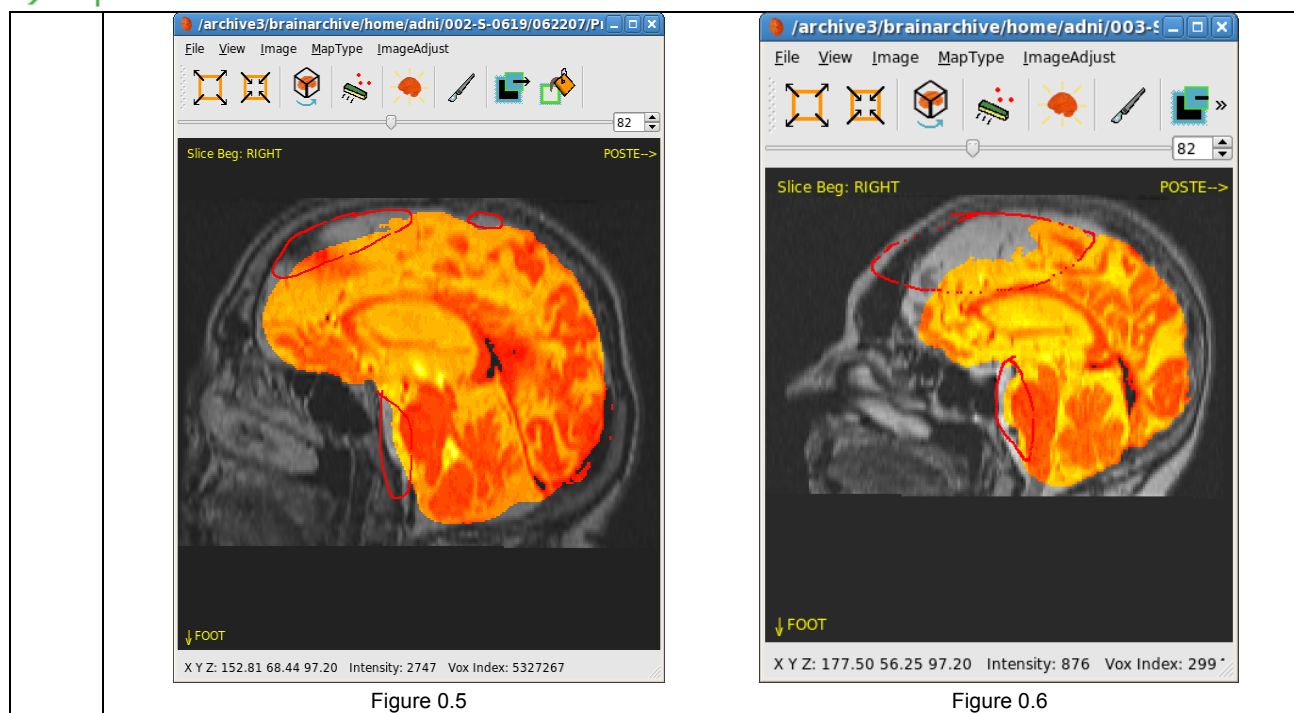


Figure 0.4





## Dataset Information

This methods document applies to the following dataset(s) available from the ADNI repository:

Dataset Name	Date Submitted
Total Intracranial Volume Brain Mask	5 July 2012

## About the Authors

This document was prepared by Phong Vuong at the University of California, Davis in the department of Neurology. For more information please contact Phong Vuong by email at [pvvuong@ucdavis.edu](mailto:pvvuong@ucdavis.edu)

*Notice: This document is presented by the author(s) as a service to ADNI data users. However, users should be aware that no formal review process has vetted this document and that ADNI cannot guarantee the accuracy or utility of this document.*